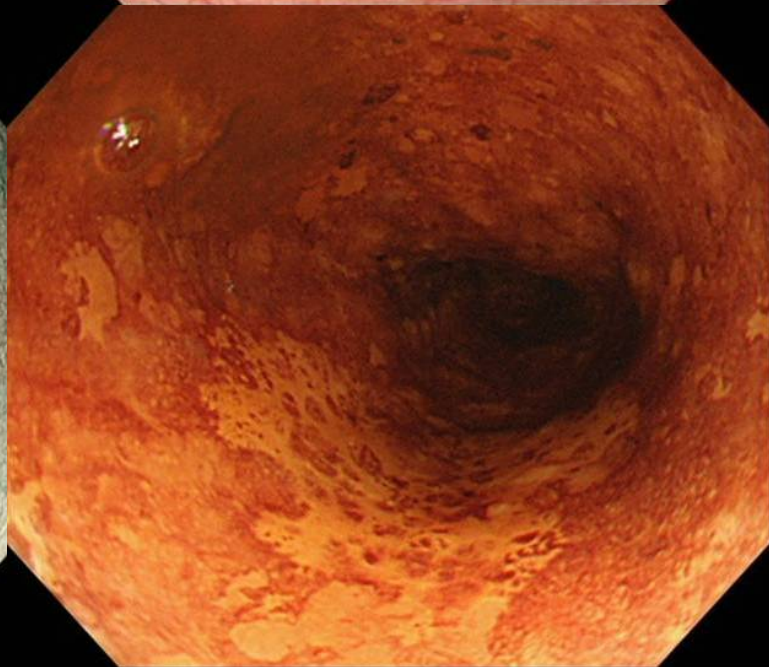
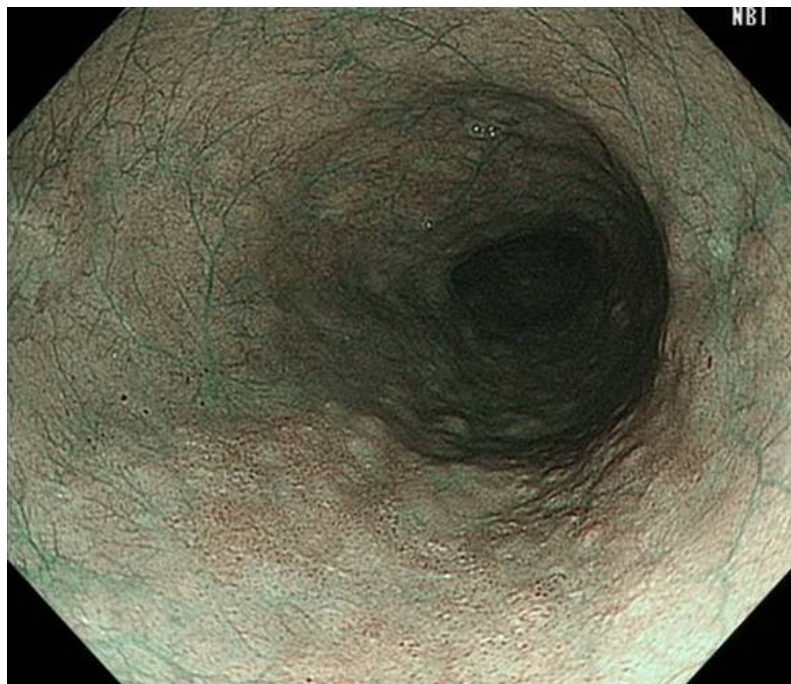
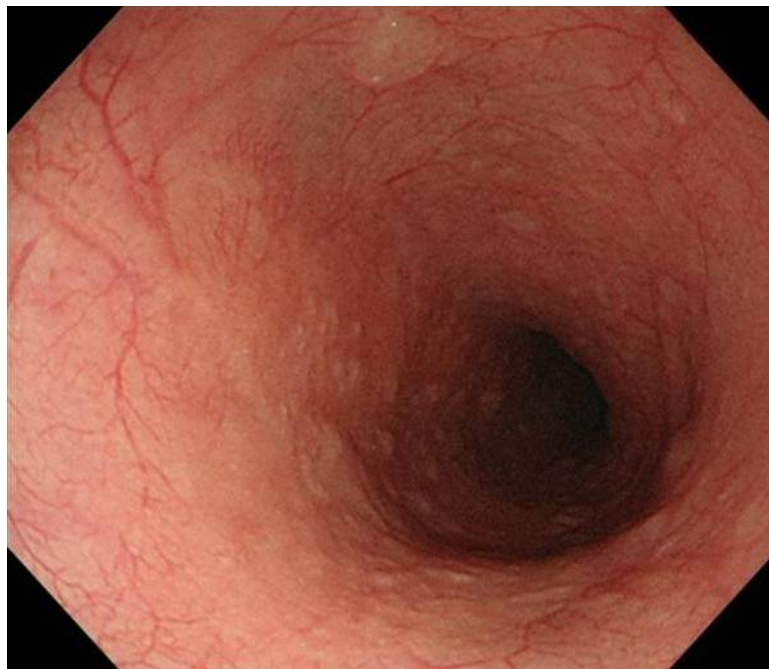
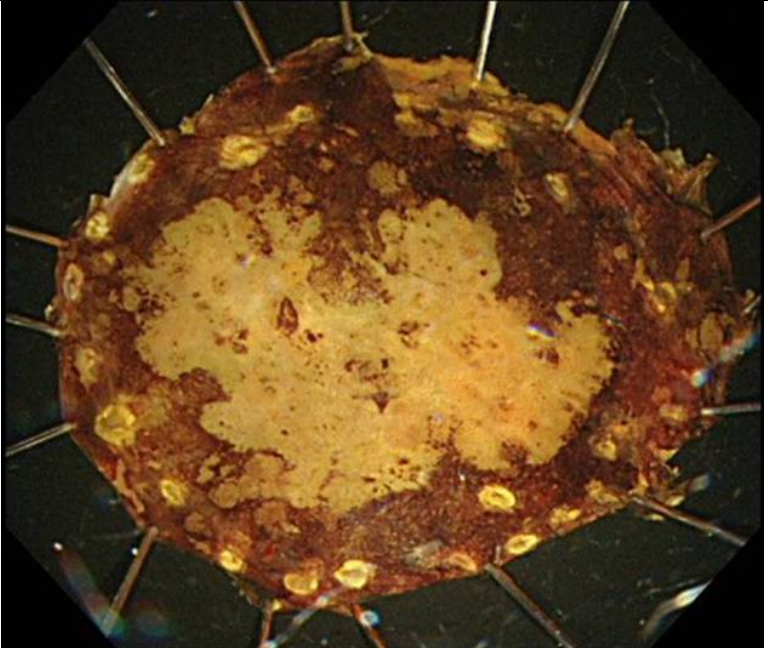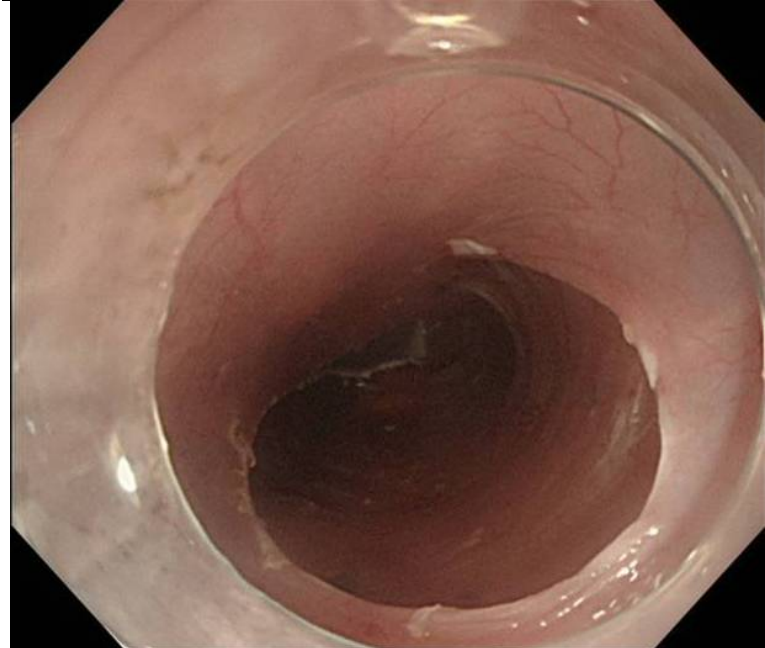
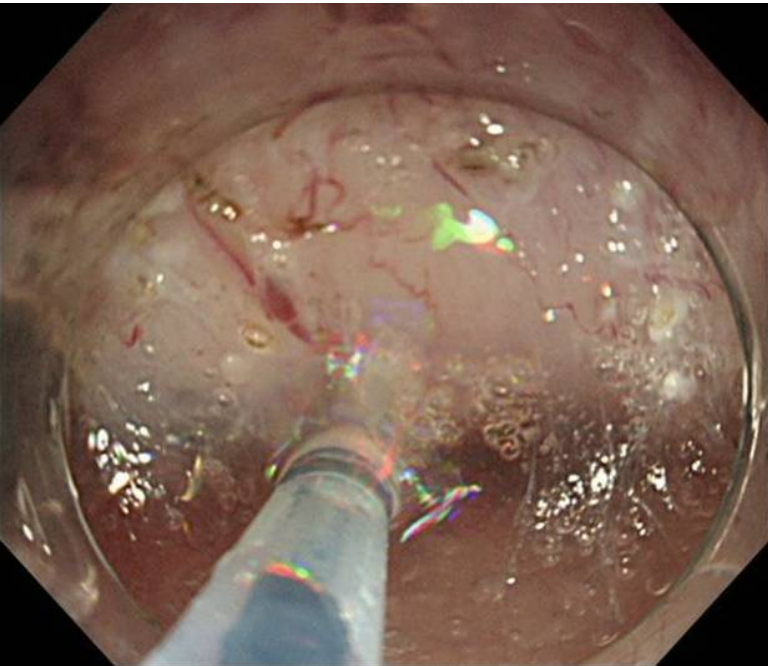

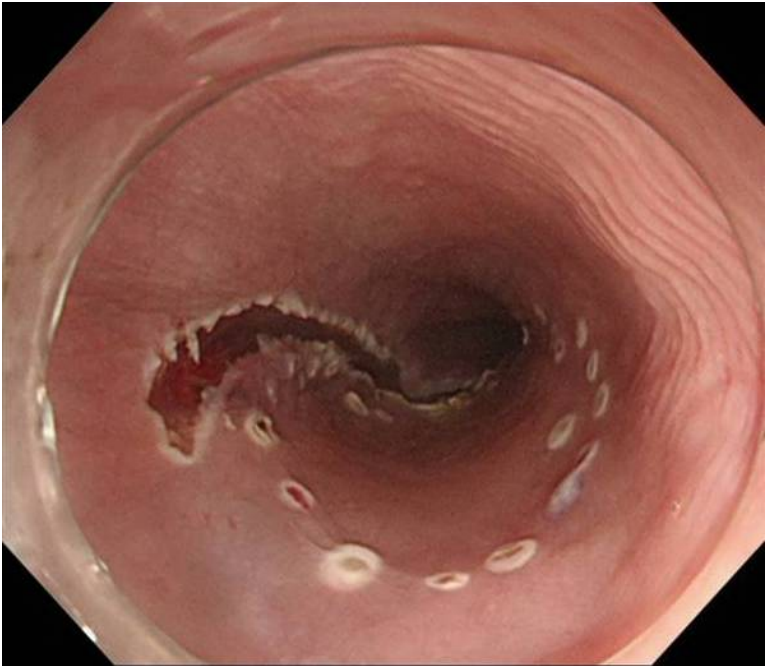

2. 食道癌粘膜切除

70歲台男性
中部食道
II b





切除標本45×30mm



Esophagus, ESD: 1) Squamous cell carcinoma, pT1a-LPM, pHM0, pVM0, pR0, ly0, v0